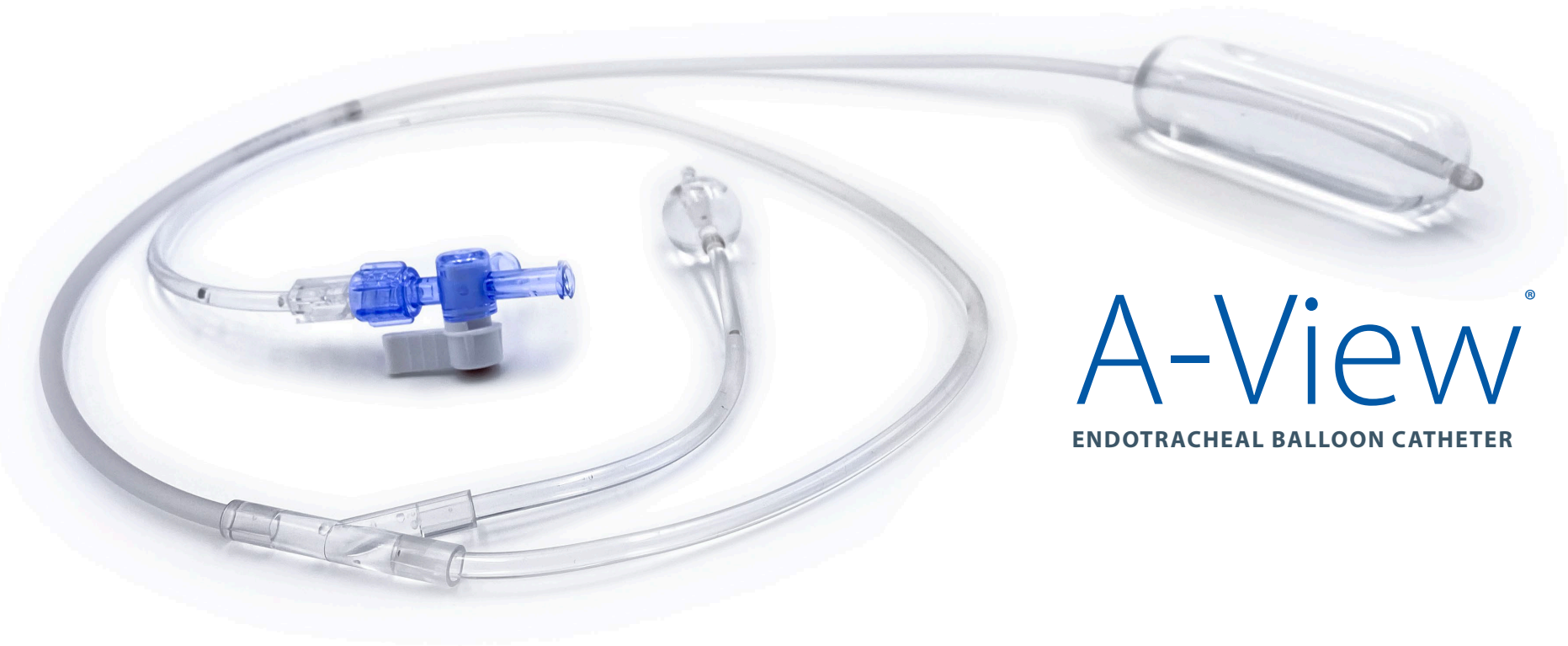




Improving Care. Improving Business.®

Vascular TEE Views

**14 safety check guideline views
including aortic arch views**



A-View®

ENDOTRACHEAL BALLOON CATHETER

deroyal.com

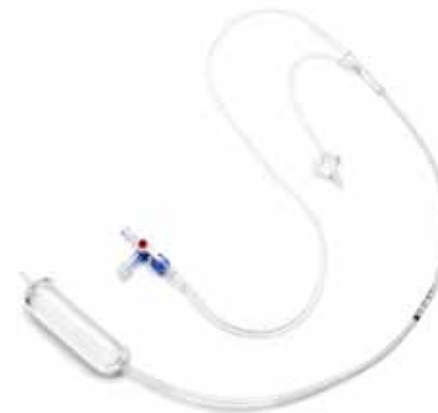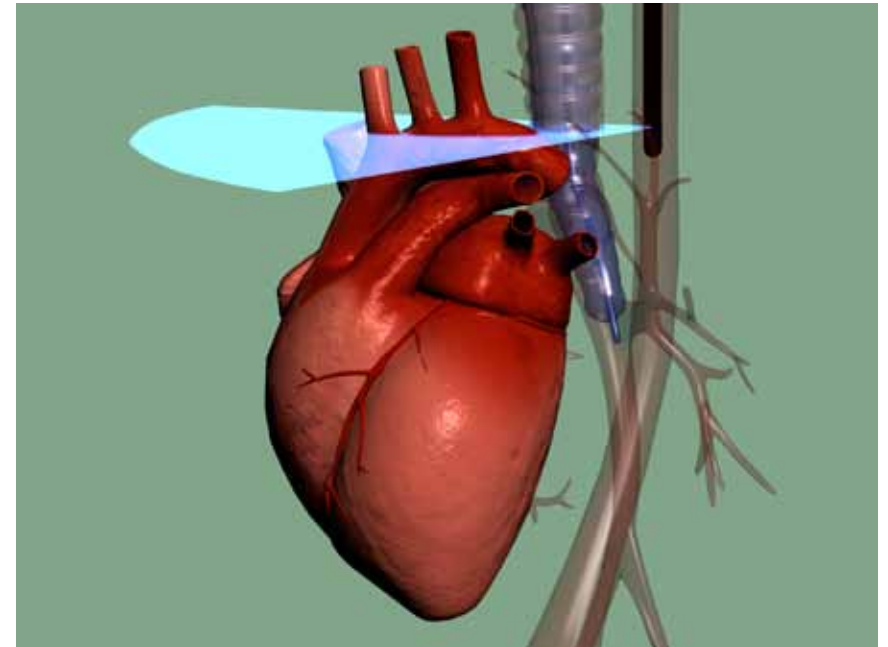
Preface

Transesophageal echocardiography (TEE) is being used in cardiothoracic surgery and interventional cardiology to create vascular views before and during cardiac surgery. Knowledge on the presence and localization of atherosclerotic plaques helps the surgeon to determine the safest surgical approach.

However, due to the position of the air-filled trachea, between the thoracic aorta and the TEE-probe, visualization of the distal ascending aorta (DAA) and Arch is impossible or mostly limited. The DAA is the location where cannulation and crossclamping takes place and where atherosclerotic plaques are most prevalent as a source of embolisms often known to be the cause of a major stroke.

A-View® Endotracheal Balloon Catheter is used to overcome the limitation of the so called 'blind spot' of TEE. After introduction of the saline filled catheter in the trachea, echo conduction through the trachea is enabled and the ascending aorta, aortic arch and its branching vessels can be imaged. For more information about A-View see our website.

The TEE safety check contains 14 TEE views of which 6 imaged with the use of the A-View® balloon. This guide, developed in conjunction with a leading cardiac anesthesiologist-intensivist, Dr. Arno Nierich, can assist in obtaining the best vascular views when utilizing the A-View® device.

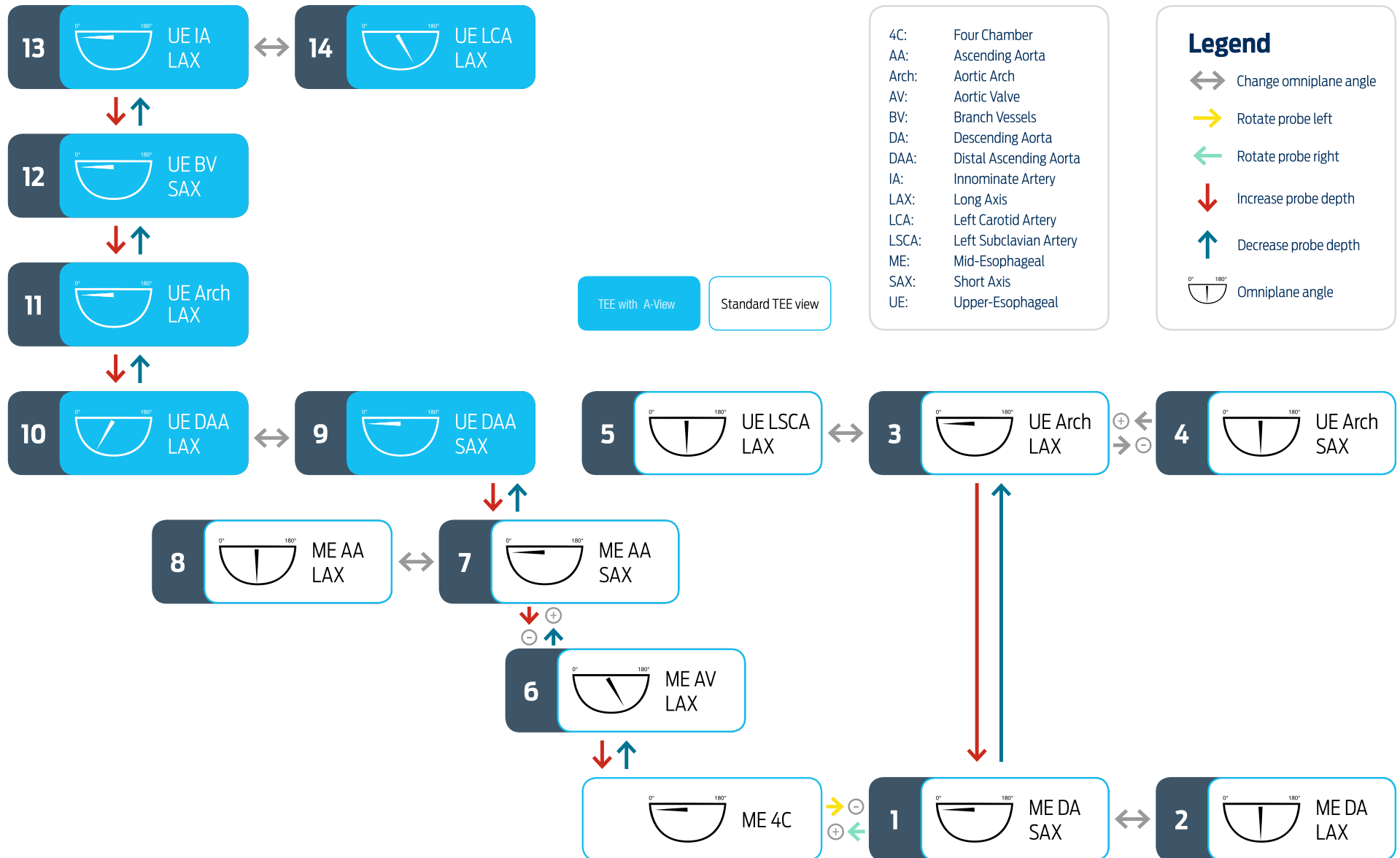


A-View®
ENDOTRACHEAL BALLOON CATHETER



*Scan here to get a
PDF of this document*

Overview Vascular TEE Views



Abbreviations

4C: Four Chamber

AA: Ascending Aorta

Arch: AorticArch

AV: Aortic Valve

BV: Branch Vessels

DA: Descending Aorta

DAA: Distal Ascending Aorta

IA: Innominate Artery

IV: Innominate Vein

LA: Left Atrium

LAX: Long Axis

LCA: LeftCarotid Artery

LSCA: Left Subclavian Artery

LVOT: Left Ventricular Outflow Tract

ME: Mid-Esophageal

PA: Pulmonary Artery

PAA: Proximal Ascending Aorta

PV: Pulmonary Valve

RPA: Right Pulmonary Artery

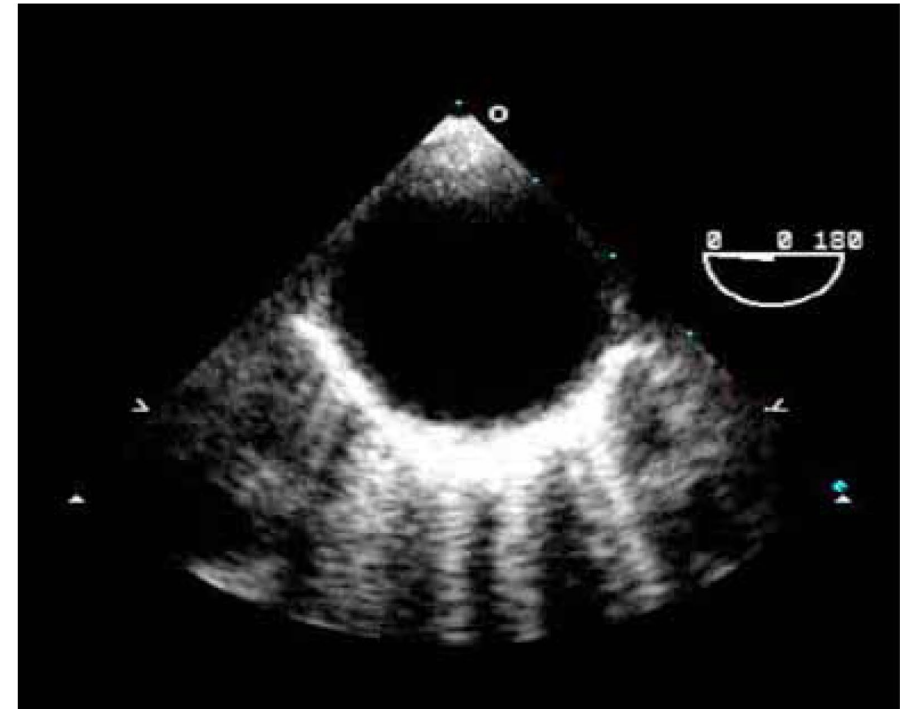
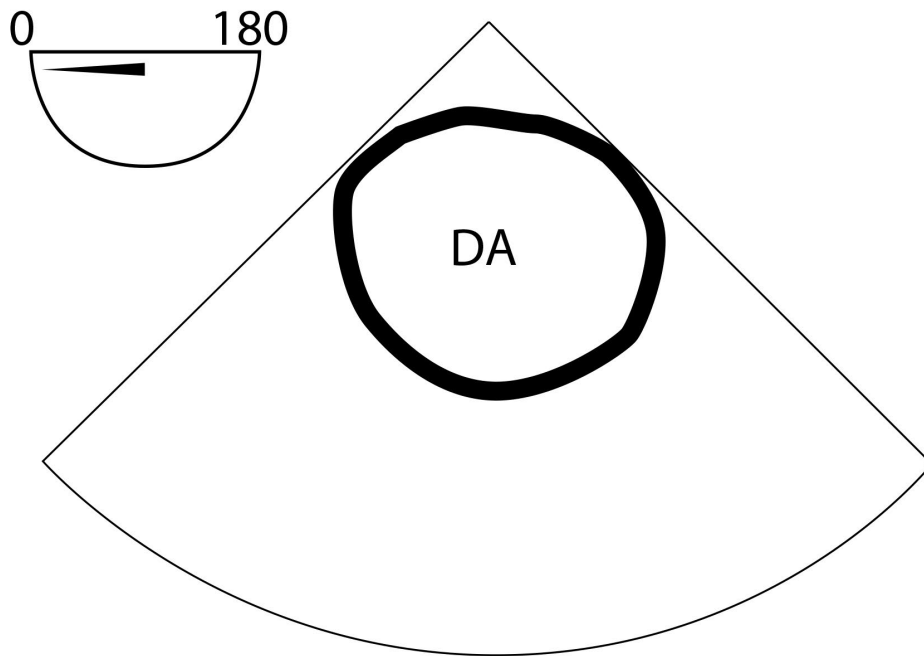
RVOT: Right Ventricular Outflow Tract

SAX: Short Axis

SVC: Superior Vena Cava

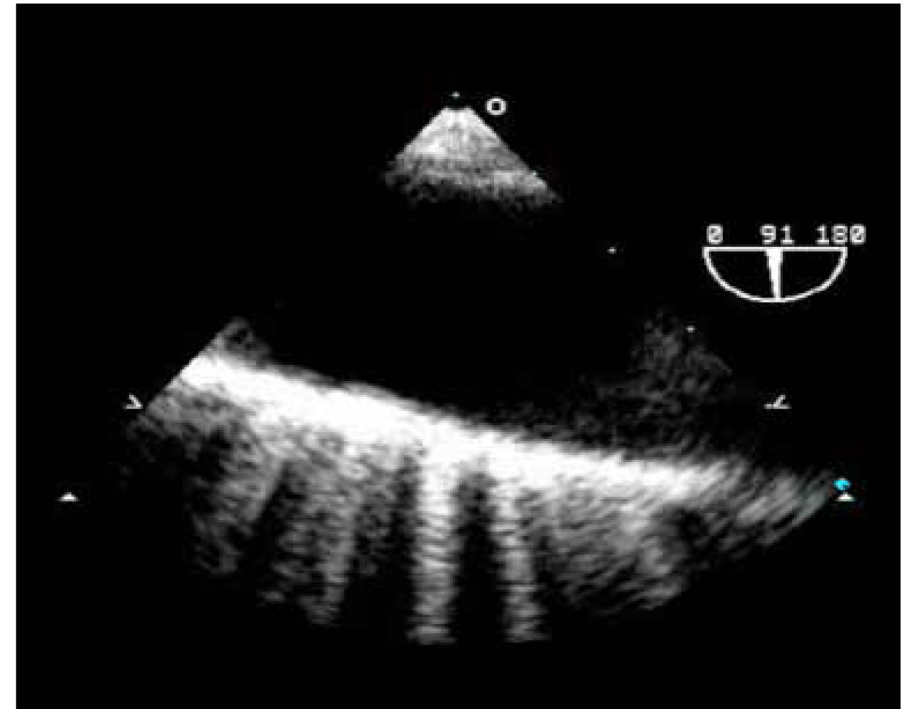
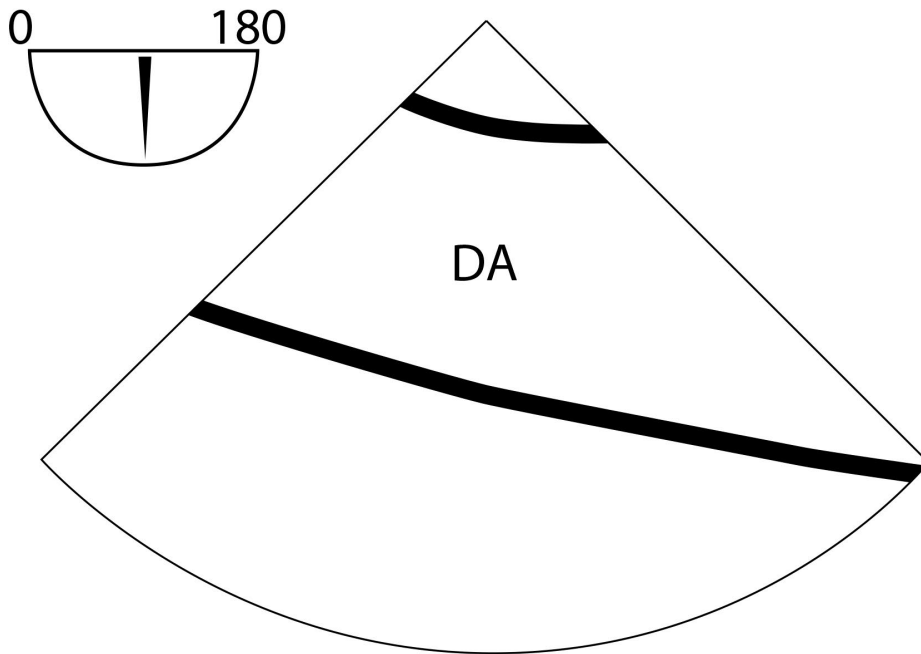
UE: Upper-Esophageal

1. ME Descending Aorta SAX View



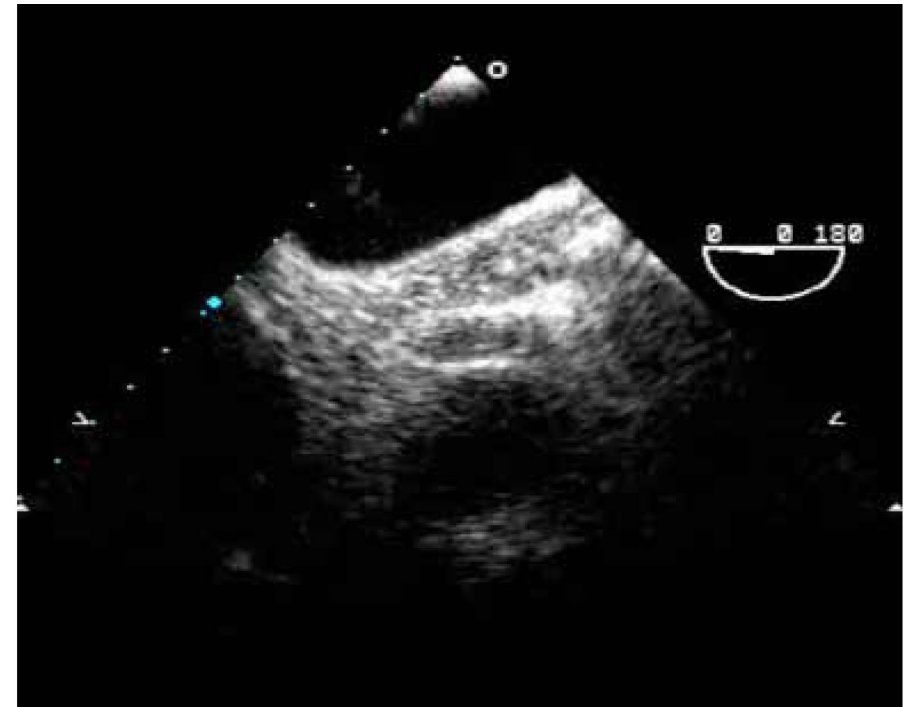
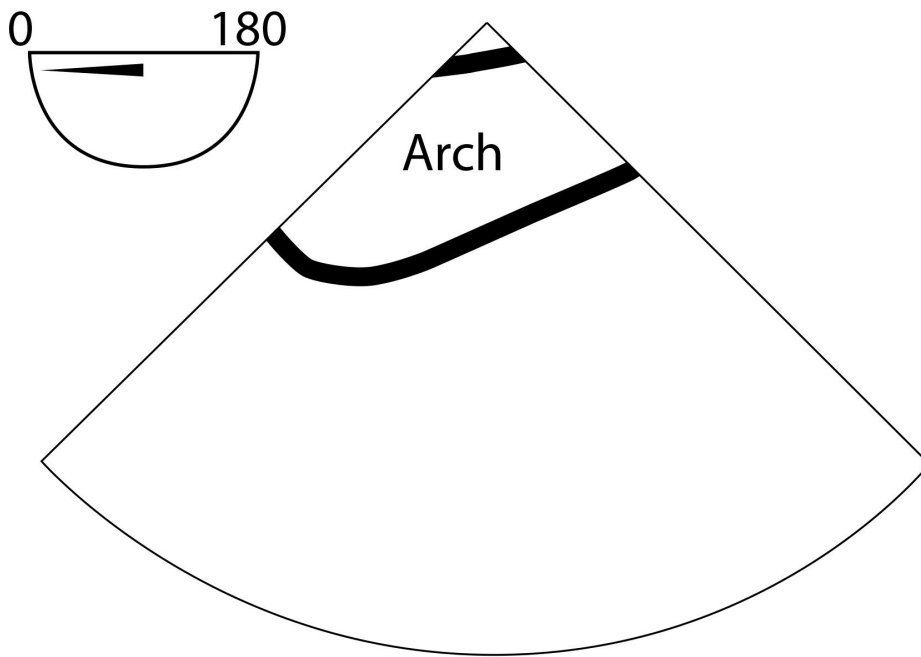
Structures to identify	To obtain this view	Diagnostic issues
AA: Ascending Aorta RPA: Right Pulmonary Artery	<ul style="list-style-type: none">• Insert the probe to the ME, sector depth 8-10 cm, angle 0°• Find the ME AV LAX (120°)• Withdraw probe to bring the Right Pulmonary Artery in view• Decrease omniplane angle slightly by 10-20° to make the aortic wall symmetric	<ul style="list-style-type: none">• Aortic Pathology• Pericardial Effusion• Pulmonary Embolus

2. ME Descending Aorta LAX



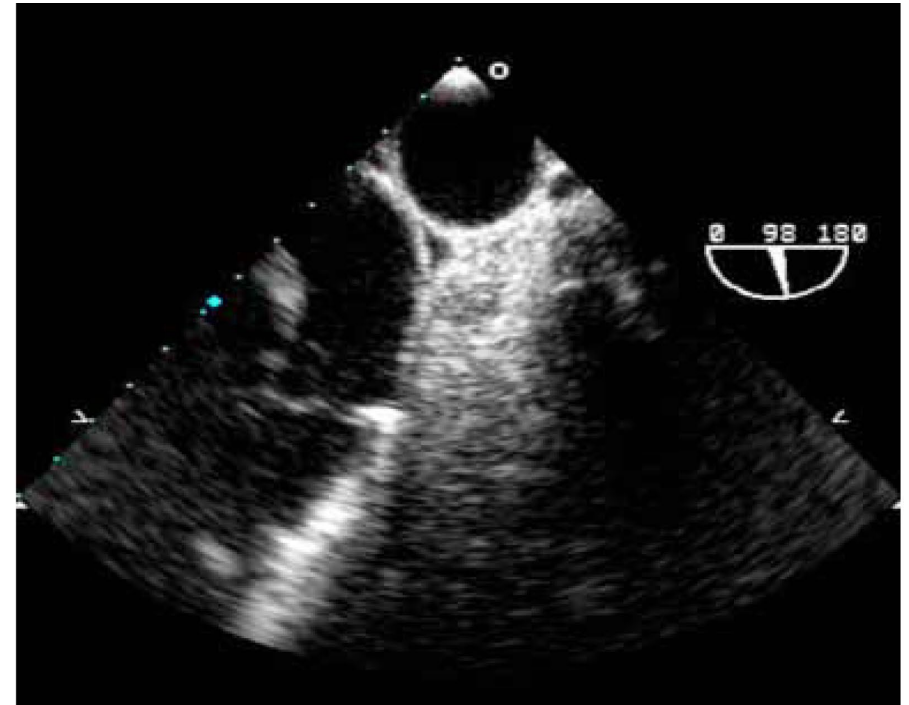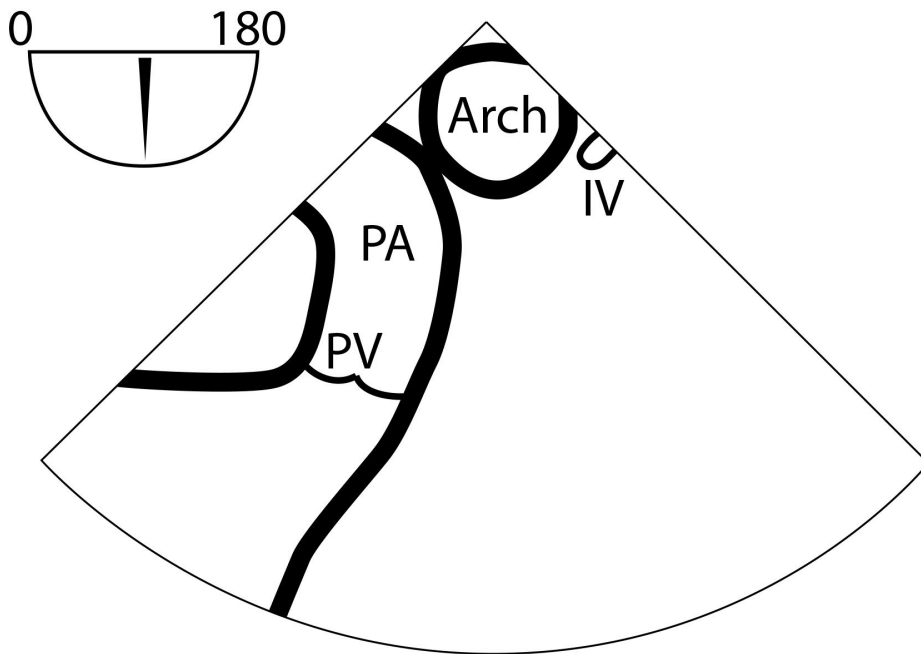
Structures to identify	To obtain this view	Diagnostic issues
<p>AA: Ascending Aorta</p> <p>RPA: Right Pulmonary Artery</p>	<ul style="list-style-type: none"> • Insert the probe to the ME, sector depth 8-10 cm, angle 0° • Find the ME AV LAX (120°) • Withdraw probe to bring the Right Pulmonary Artery in view • Decrease omniplane angle slightly by 10-20° to make the aortic wall symmetric 	<ul style="list-style-type: none"> • Aortic Pathology • Pericardial Effusion • Pulmonary Embolus

3. UE Aortic Arch LAX



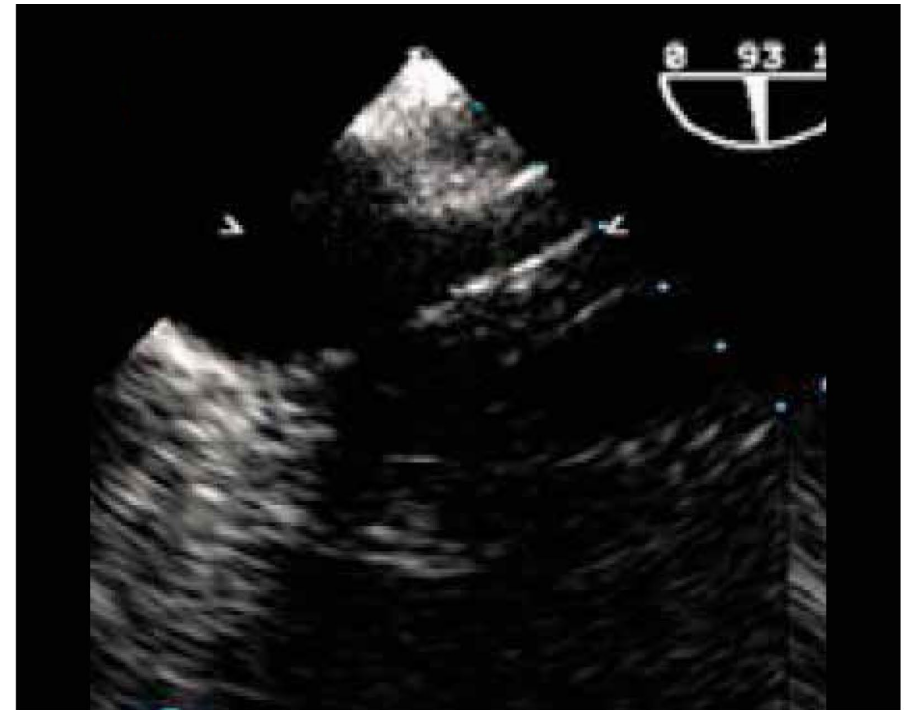
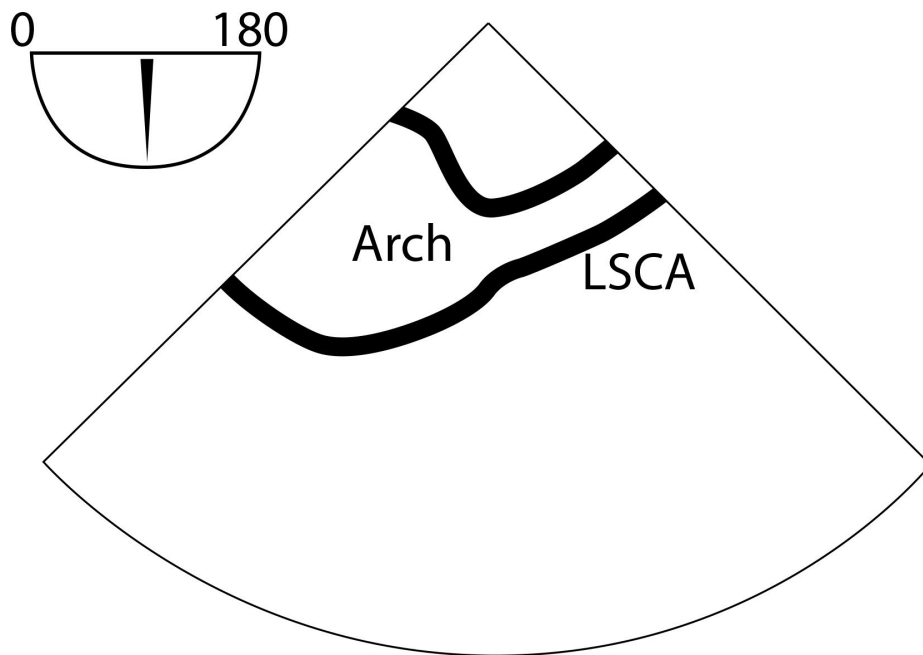
Structures to identify	To obtain this view	Diagnostic issues
<p>AA: Ascending Aorta</p> <p>RPA: Right Pulmonary Artery</p>	<ul style="list-style-type: none"> • Insert the probe to the ME, sector depth 8-10 cm, angle 0° • Find the ME AV LAX (120°) • Withdraw probe to bring the Right Pulmonary Artery in view • Decrease omniplane angle slightly by 10-20° to make the aortic wall symmetric 	<ul style="list-style-type: none"> • Aortic Pathology • Pericardial Effusion • Pulmonary Embolus

4. UE Aortic Arch SAX



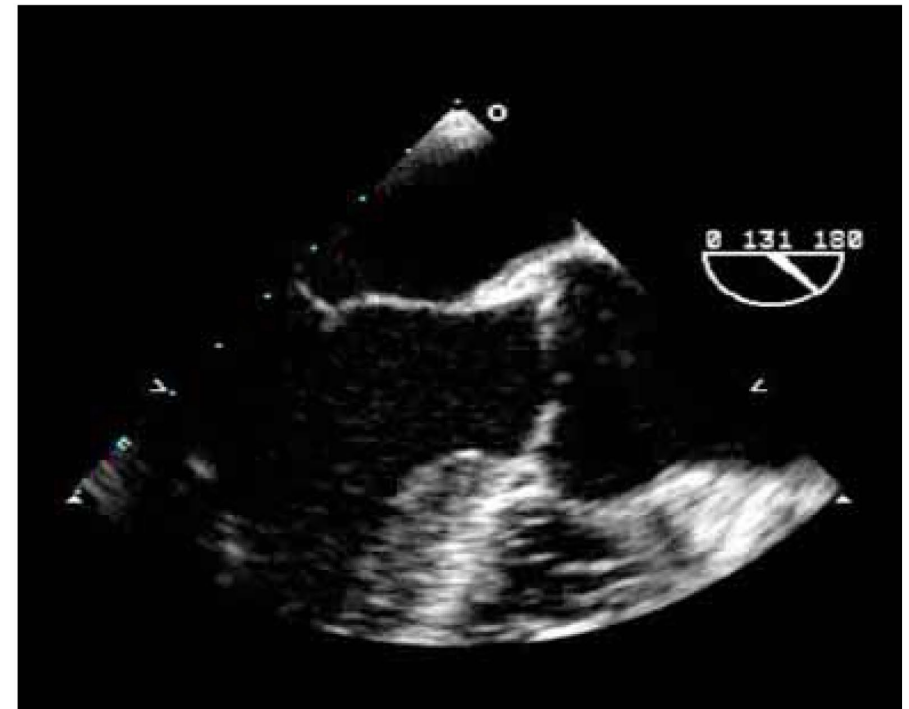
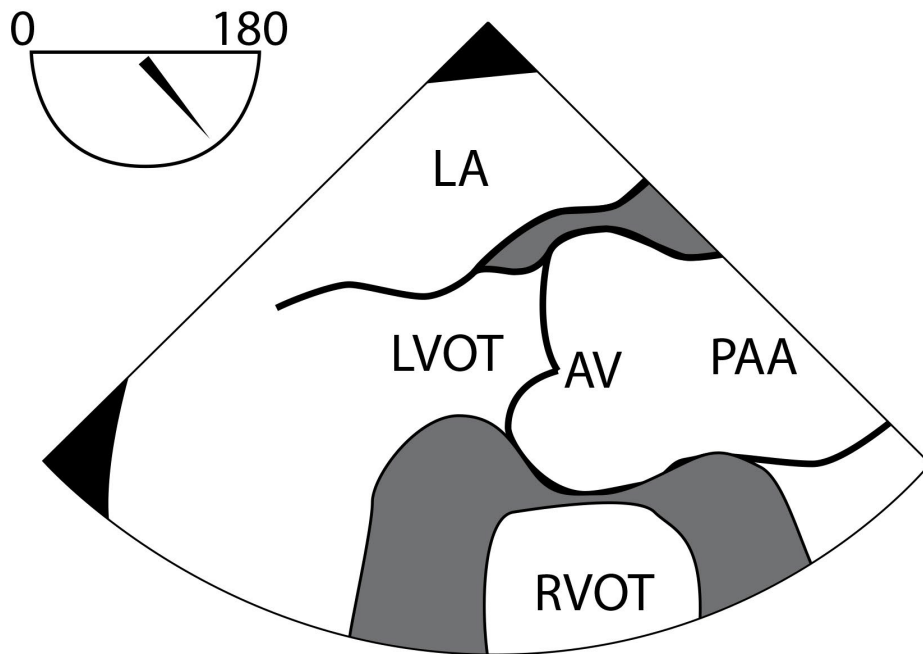
Structures to identify	To obtain this view	Diagnostic issues
AA: Ascending Aorta RPA: Right Pulmonary Artery	<ul style="list-style-type: none"> • Insert the probe to the ME, sector depth 8-10 cm, angle 0° • Find the ME AV LAX (120°) • Withdraw probe to bring the Right Pulmonary Artery in view • Decrease omniplane angle slightly by 10-20° to make the aortic wall symmetric 	<ul style="list-style-type: none"> • Aortic Pathology • Pericardial Effusion • Pulmonary Embolus

5. UE Left Subclavian Artery SAX



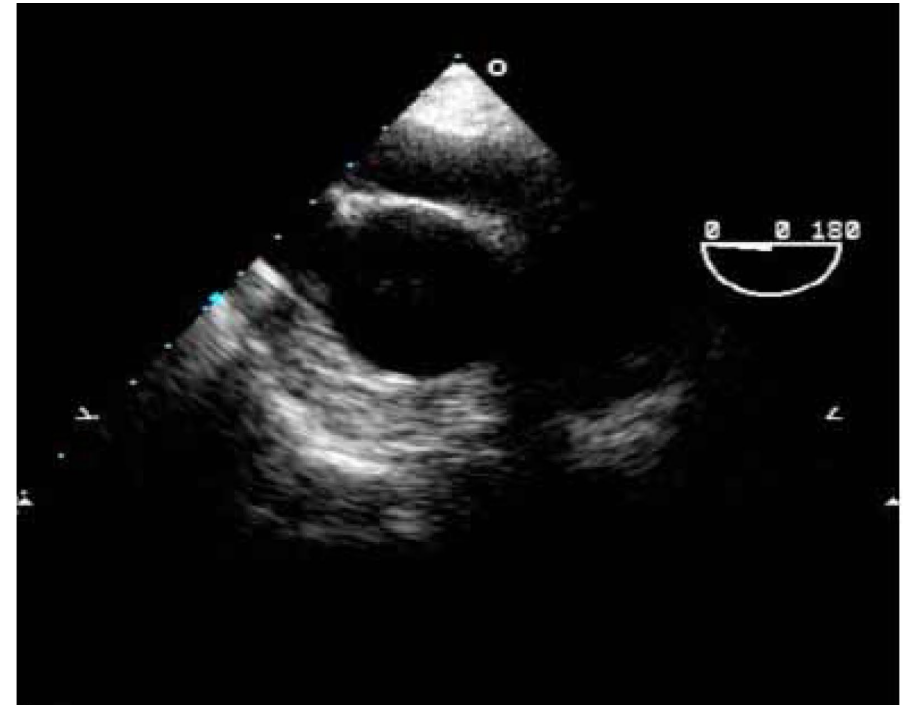
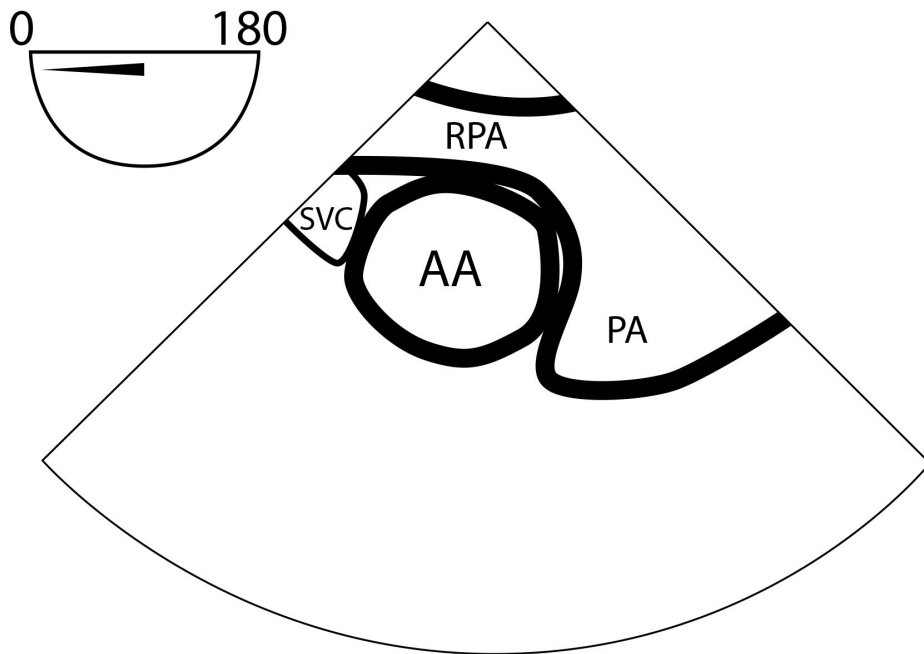
Structures to identify	To obtain this view	Diagnostic issues
<p>AA: Ascending Aorta RPA: Right Pulmonary Artery</p>	<ul style="list-style-type: none"> • Insert the probe to the ME, sector depth 8-10 cm, angle 0° • Find the ME AV LAX (120°) • Withdraw probe to bring the Right Pulmonary Artery in view • Decrease omniplane angle slightly by 10-20° to make the aortic wall symmetric 	<ul style="list-style-type: none"> • Aortic Pathology • Pericardial Effusion • Pulmonary Embolus

6. ME Aortic Valve LAX



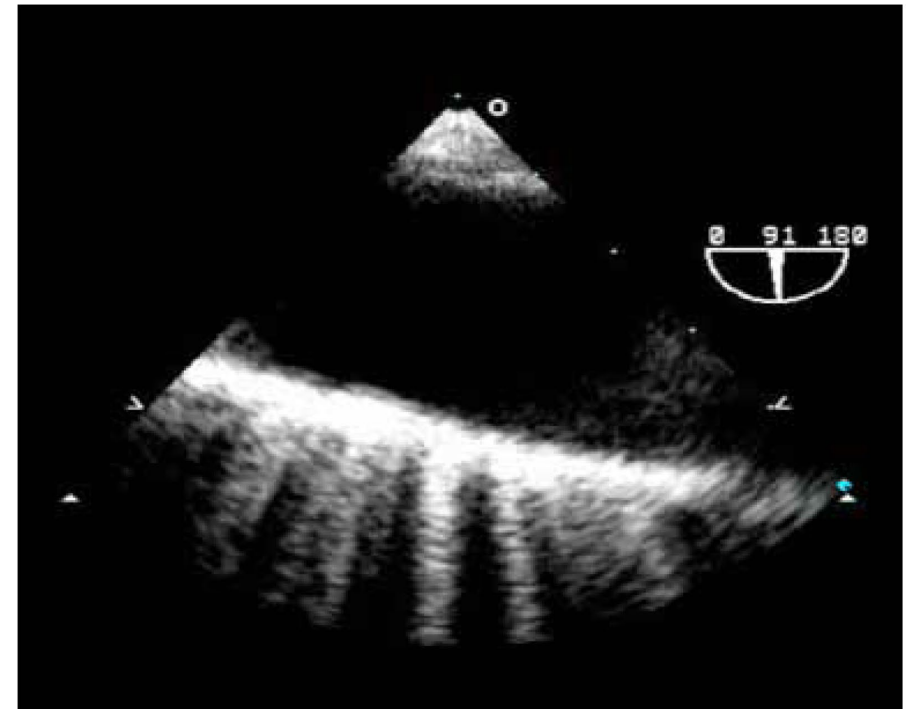
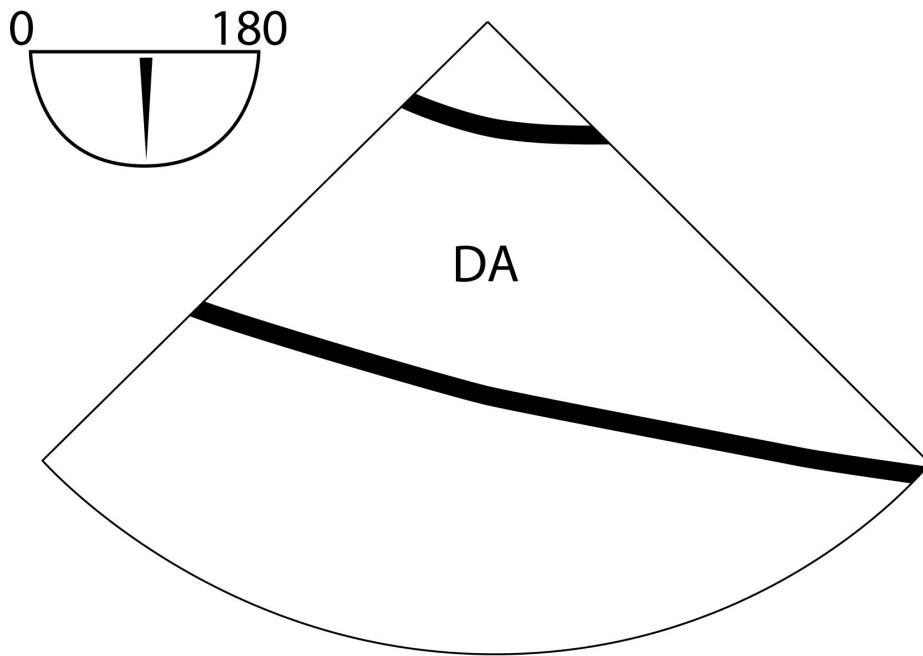
Structures to identify	To obtain this view	Diagnostic issues
<p>AA: Ascending Aorta RPA: Right Pulmonary Artery</p>	<ul style="list-style-type: none"> • Insert the probe to the ME, sector depth 8-10 cm, angle 0° • Find the ME AV LAX (120°) • Withdraw probe to bring the Right Pulmonary Artery in view • Decrease omniplane angle slightly by 10-20° to make the aortic wall symmetric 	<ul style="list-style-type: none"> • Aortic Pathology • Pericardial Effusion • Pulmonary Embolus

7. ME Ascending Aorta SAX



Structures to identify	To obtain this view	Diagnostic issues
<p>AA: Ascending Aorta</p> <p>RPA: Right Pulmonary Artery</p>	<ul style="list-style-type: none"> • Insert the probe to the ME, sector depth 8-10 cm, angle 0° • Find the ME AV LAX (120°) • Withdraw probe to bring the Right Pulmonary Artery in view • Decrease omniplane angle slightly by 10-20° to make the aortic wall symmetric 	<ul style="list-style-type: none"> • Aortic Pathology • Pericardial Effusion • Pulmonary Embolus

8. ME Ascending Aorta LAX

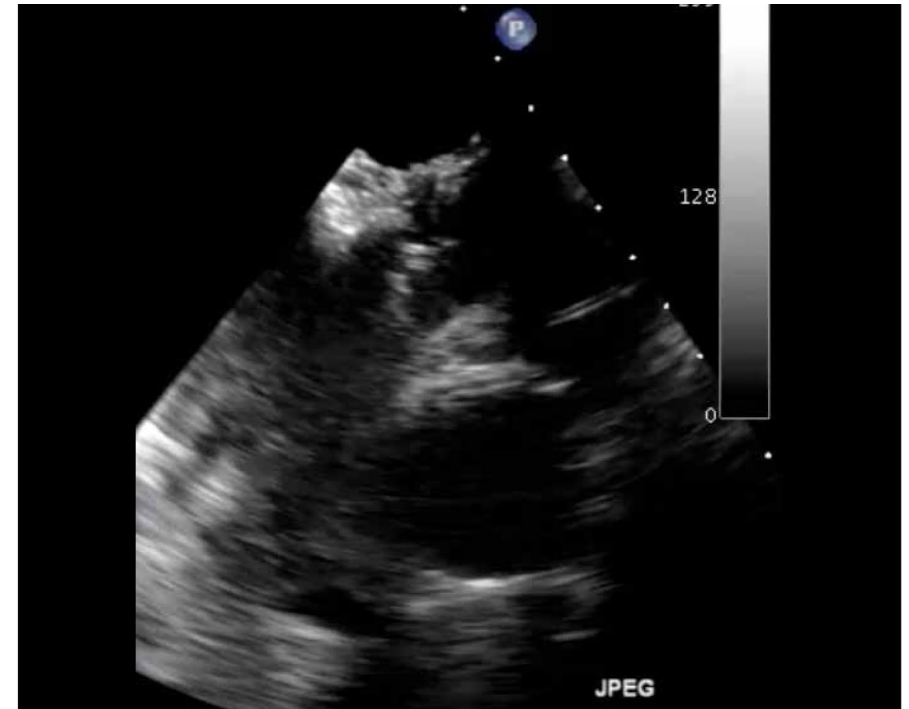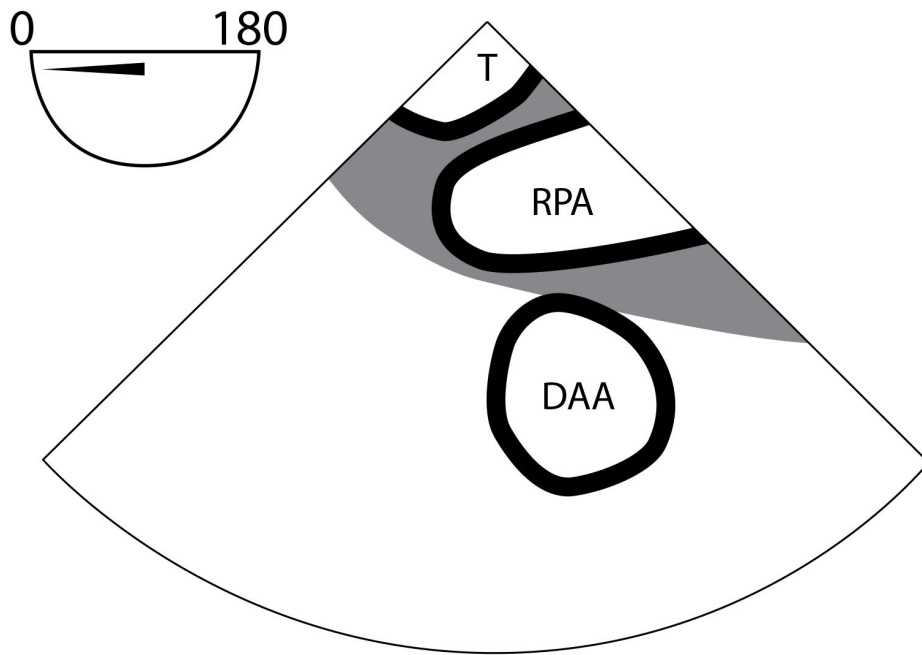


Structures to identify	To obtain this view	Diagnostic issues
<p>AA: Ascending Aorta RPA: Right Pulmonary Artery</p>	<ul style="list-style-type: none"> • Insert the probe to the ME, sector depth 8-10 cm, angle 0° • Find the ME AV LAX (120°) • Withdraw probe to bring the Right Pulmonary Artery in view • Decrease omniplane angle slightly by 10-20° to make the aortic wall symmetric 	<ul style="list-style-type: none"> • Aortic Pathology • Pericardial Effusion • Pulmonary Embolus

Getting Started

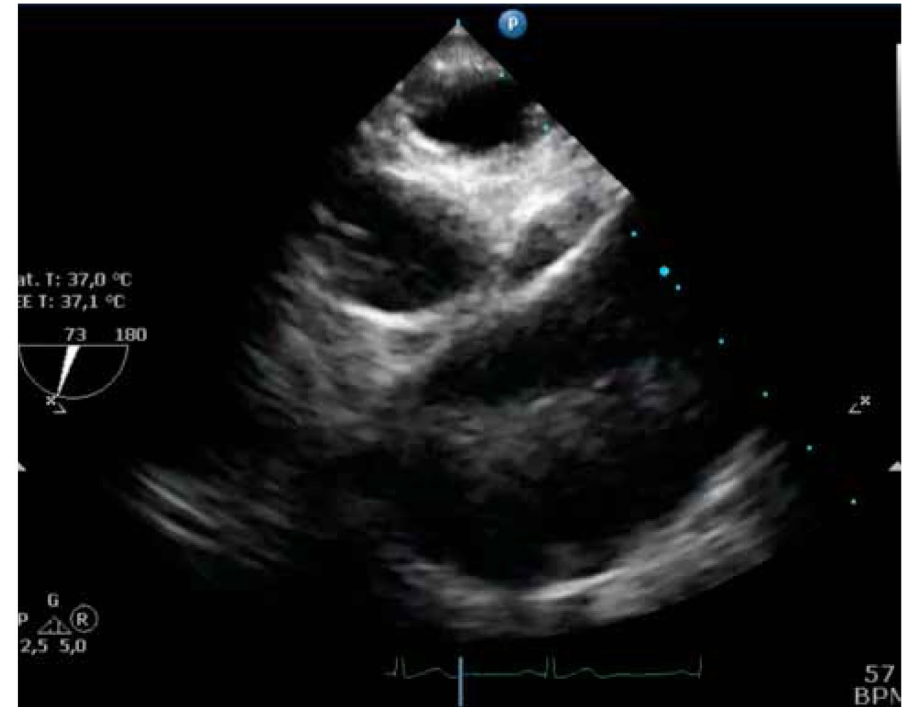
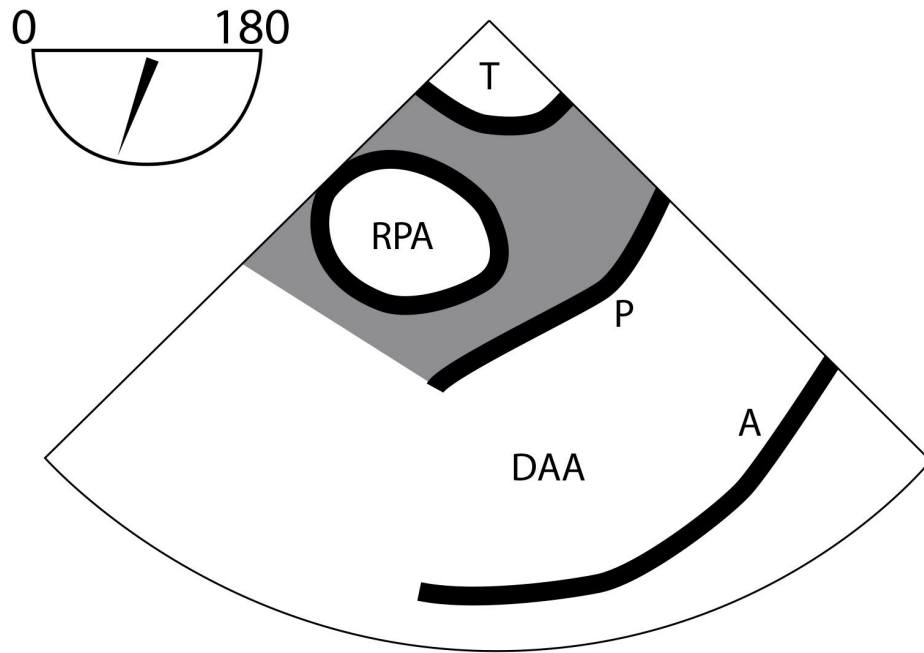
1. Find the ME Ascending Aorta SAX view, withdraw the probe to the UE, sector depth 10 cm, angle 30°
2. Anteflex probe slightly
3. Withdraw the probe till entering the blind spot area
4. Leave the probe in this position and insert the A-View[®]
5. Proceed to obtain the following 6 views

9. UE Distal Ascending Aorta SAX A-View®



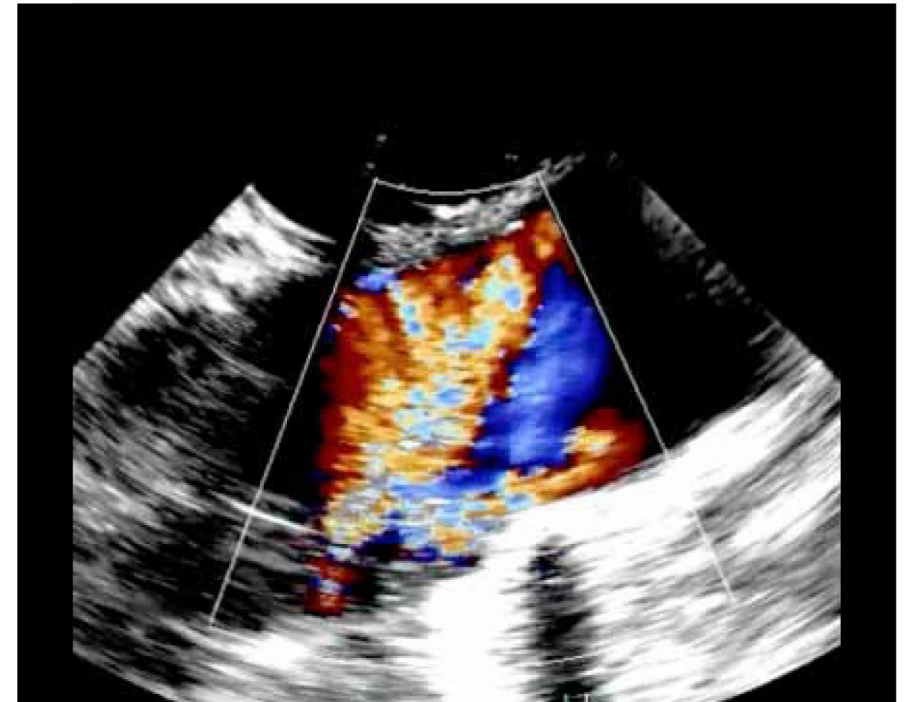
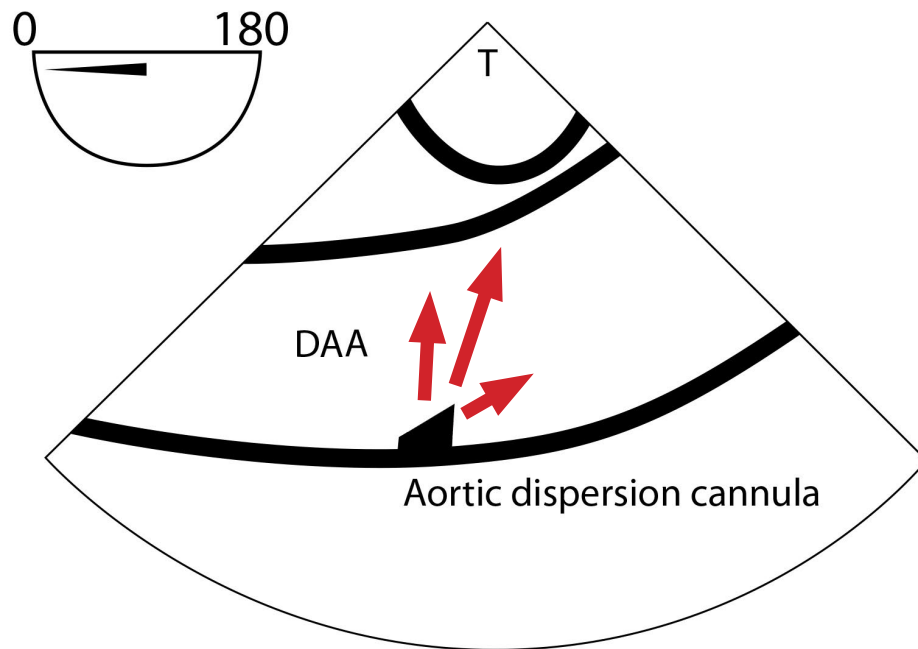
Structures to identify	To obtain this view	Diagnostic issues
<p>DAA: Distal Ascending Aorta</p> <p>RPA: Right Pulmonary Artery</p> <p>T: Trachea with A-View</p>	<ul style="list-style-type: none"> • Find ME AA SAX • Withdraw probe slightly to UE position, with the sector depth 10 cm, angle 0-30° • The trachea will become visible or the right or left bronchus • Keep the Aorta centered before rotate to 60° • Aorta will become visible as a tube directed to the right upper screen position 	<ul style="list-style-type: none"> • Atherosclerotic Disease • Aortic Dissection • Pulmonary Embolus

10. UE Distal Ascending Aorta LAX A-View®



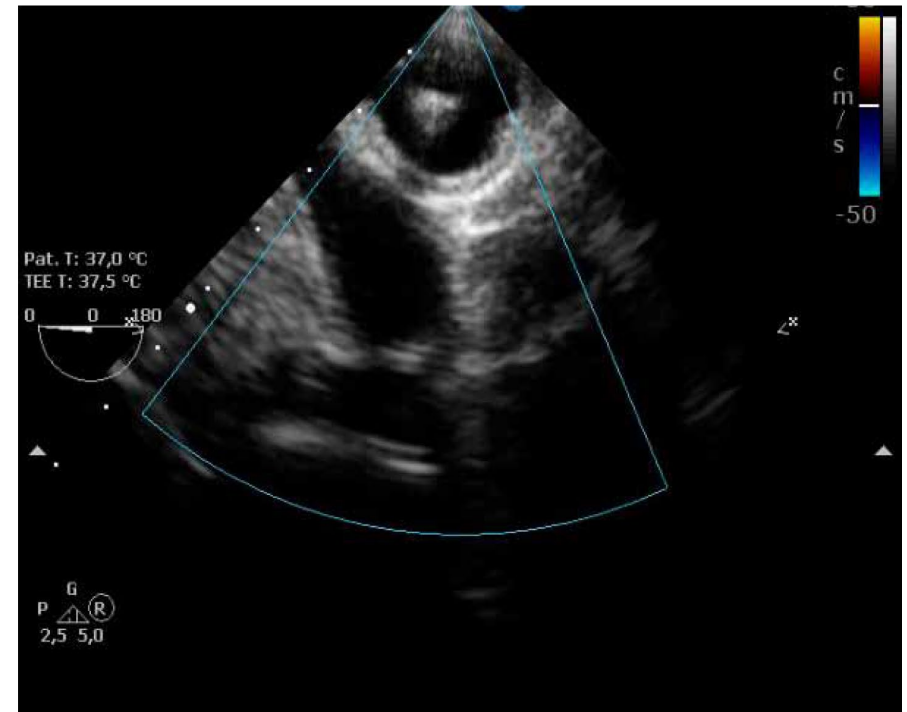
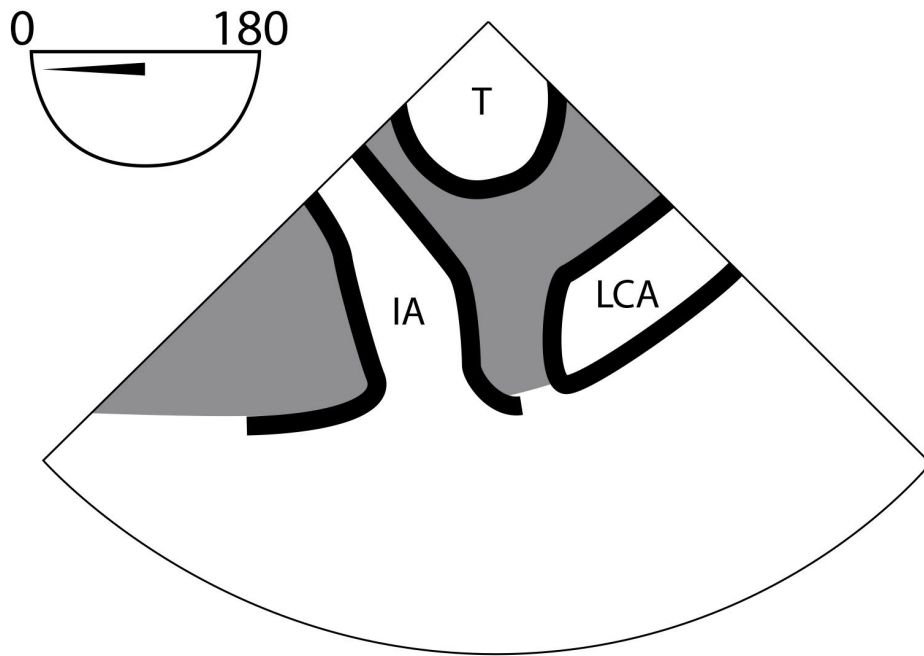
Structures to identify	To obtain this view	Diagnostic issues
<p>DAA: Distal Ascending Aorta</p> <p>T: Trachea with A-View</p>	<ul style="list-style-type: none"> Find UE DAA SAX (0°) view, sector depth 6-8 cm Keep the trachea centered Only move the probe, A-View remains in the same location Use color Doppler to verify arterial flow 	<ul style="list-style-type: none"> Atherosclerotic Disease Aortic Dissection Extracorporeal Circulation (ECC) Vascular Devices (cannulation and flow)

11. UE Aortic Arch SAX A-View®



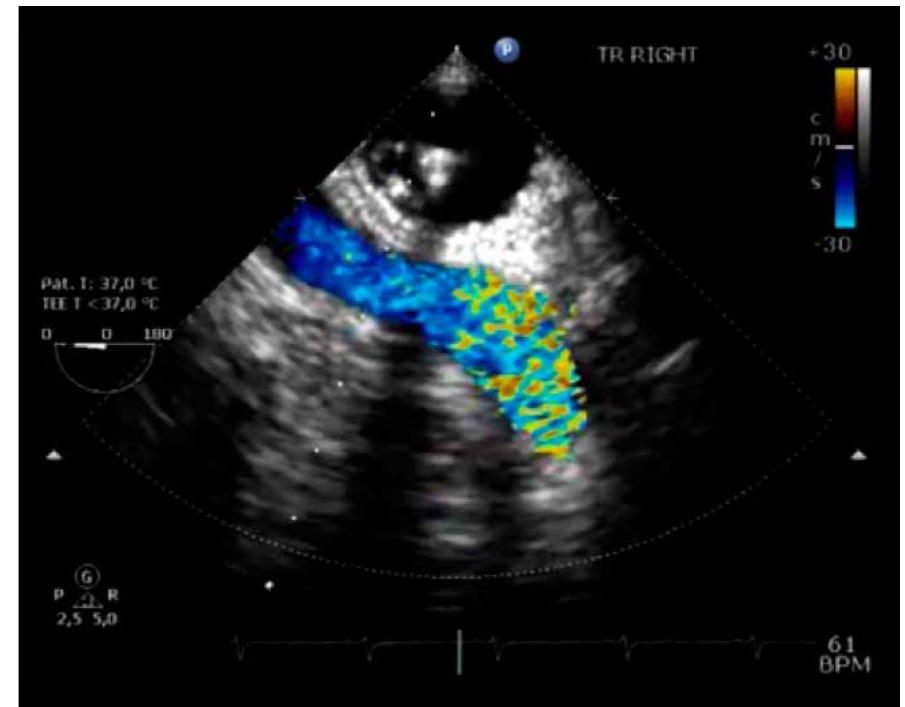
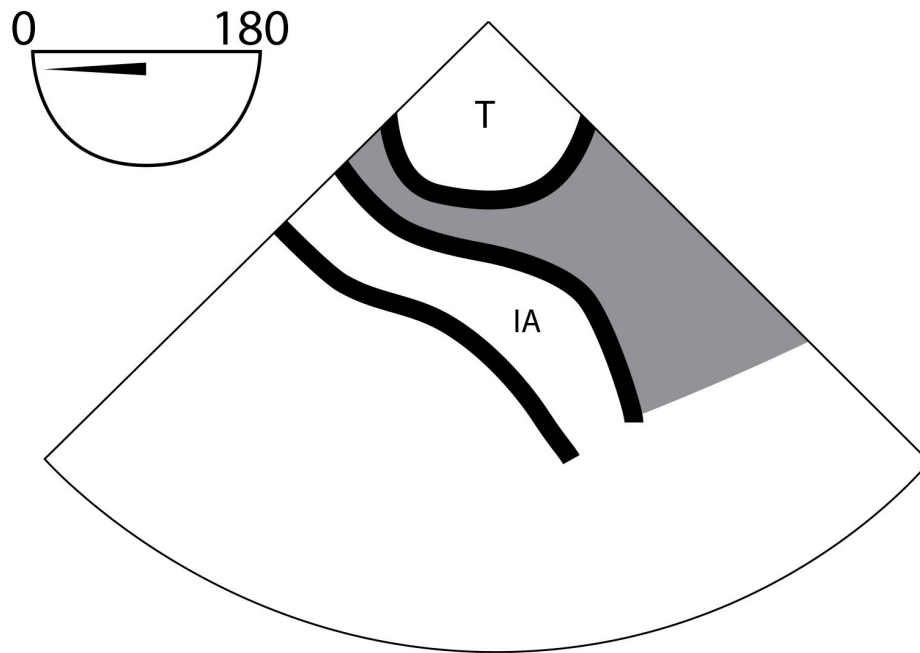
Structures to identify	To obtain this view	Diagnostic issues
<p>DA: Upper part of the Descending Aorta</p> <p>T: Trachea with A-View</p>	<ul style="list-style-type: none"> Find the UE Aortic Arch, position sector depth 6-8cm, angle 0° Keep the trachea centered Only move the probe, A-View remains at the same location Use color Doppler to verify arterial flow 	<ul style="list-style-type: none"> Aortic Atherosclerosis Aortic Dissection Extracorporeal Circulation (ECC) Vascular Devices (cannulation and flow)

12. UE Branch Vessels LAX A-View®



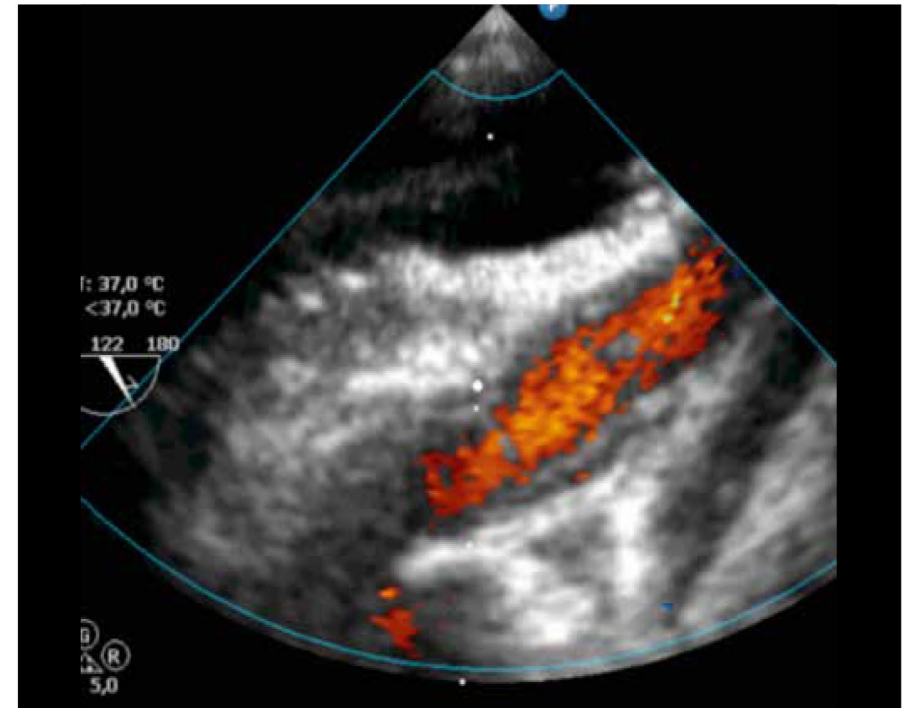
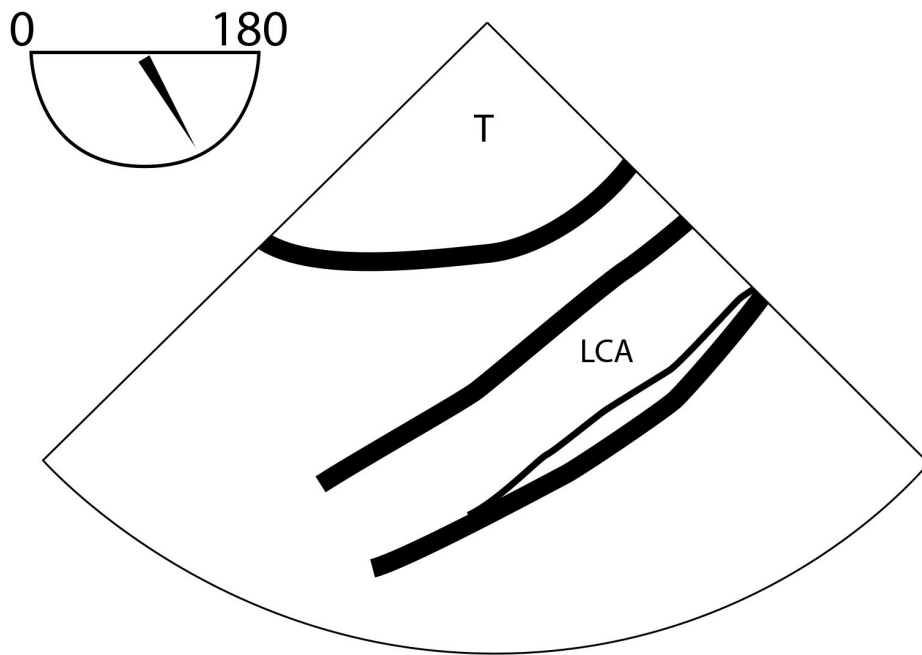
Structures to identify	To obtain this view	Diagnostic issues
IA: Innominate Artery LCA: Left Carotid Artery T: Trachea with A-View	<ul style="list-style-type: none"> Find the UE Aortic Arch LAX (0°) view Position sector depth 6-8 cm, withdraw the probe slightly Use color Doppler to verify arterial flow 	<ul style="list-style-type: none"> Atherosclerotic Disease Aortic Dissection Extracorporeal Circulation (ECC) Antegrade Cerebral Perfusion

13. UE Innominate Artery LAX A-View®



Structures to identify	To obtain this view	Diagnostic issues
IA: Innominate Artery T: Trachea with A-View	<ul style="list-style-type: none"> Find the UE Aortic Arch LAX (0°) view Position sector depth 6-8 cm, withdraw the probe slightly and turn probe to the right Use color Doppler to verify arterial flow 	<ul style="list-style-type: none"> Atherosclerotic Disease Aortic Dissection Extracorporeal Circulation (ECC) Antegrade Cerebral Perfusion Vascular Devices

14. UE Left Carotid A-View®



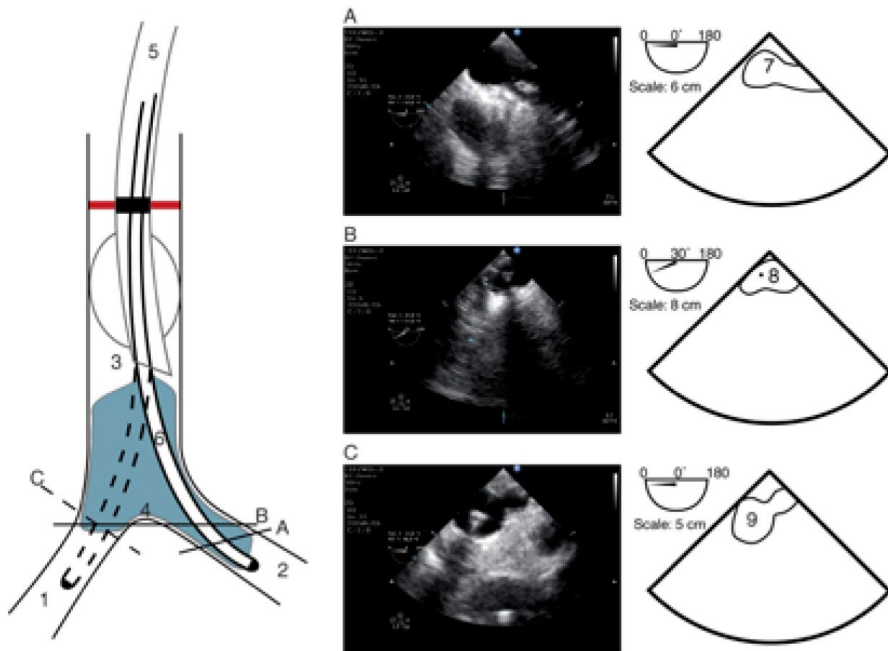
Structures to identify	To obtain this view	Diagnostic issues
<p>LCA: Left Carotid Artery</p> <p>T: Trachea with A-View</p>	<ul style="list-style-type: none"> • Find the UE Aortic Arch LAX (0°) view • Slightly withdraw and rotate the probe to the left • Use color Doppler to verify arterial flow 	<ul style="list-style-type: none"> • Atherosclerotic Disease • Aortic Dissection • Extracorporeal Circulation (ECC) • Antegrade Cerebral Perfusion • Vascular Devices

Advanced user guidance

Below suggestions address specific situations. Please consult the "Instructions for Use" for routine application of A-View®.

To verify positioning of the A-View

The optimal position of the A-View® catheter is in the distal trachea and the left main bronchus, although this correlation to the position of the aorta might vary according to patient anatomy. Below image shows the position of A-View® in the trachea and the left main bronchus. (A) Placement into the left main bronchus, (B) TEE view of carina, and (C) placement into the right main bronchus.



Legend:

- | | |
|------------------------|---|
| 1. Right main bronchus | 6. A-View® |
| 2. Left main bronchus | 7. A-View® into the left main bronchus |
| 3. Trachea | 8. A-View® at the carina |
| 4. Carina | 9. A-View® into the right main bronchus |
| 5. ET tube | |

Difficulties to obtain distal ascending aorta views?

Check the following:

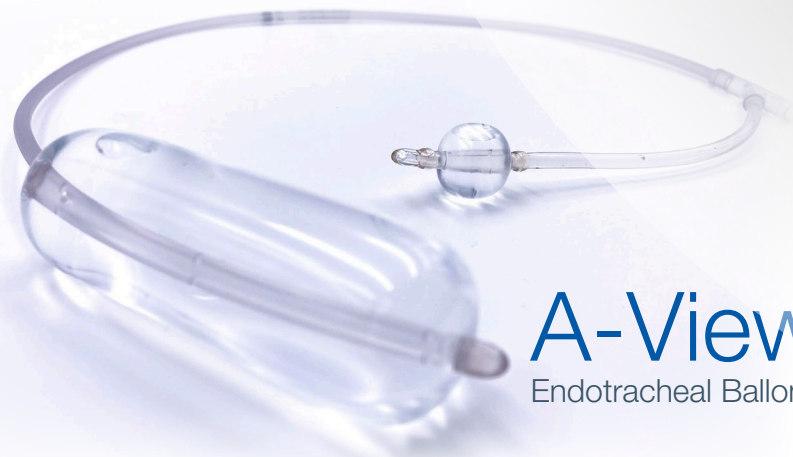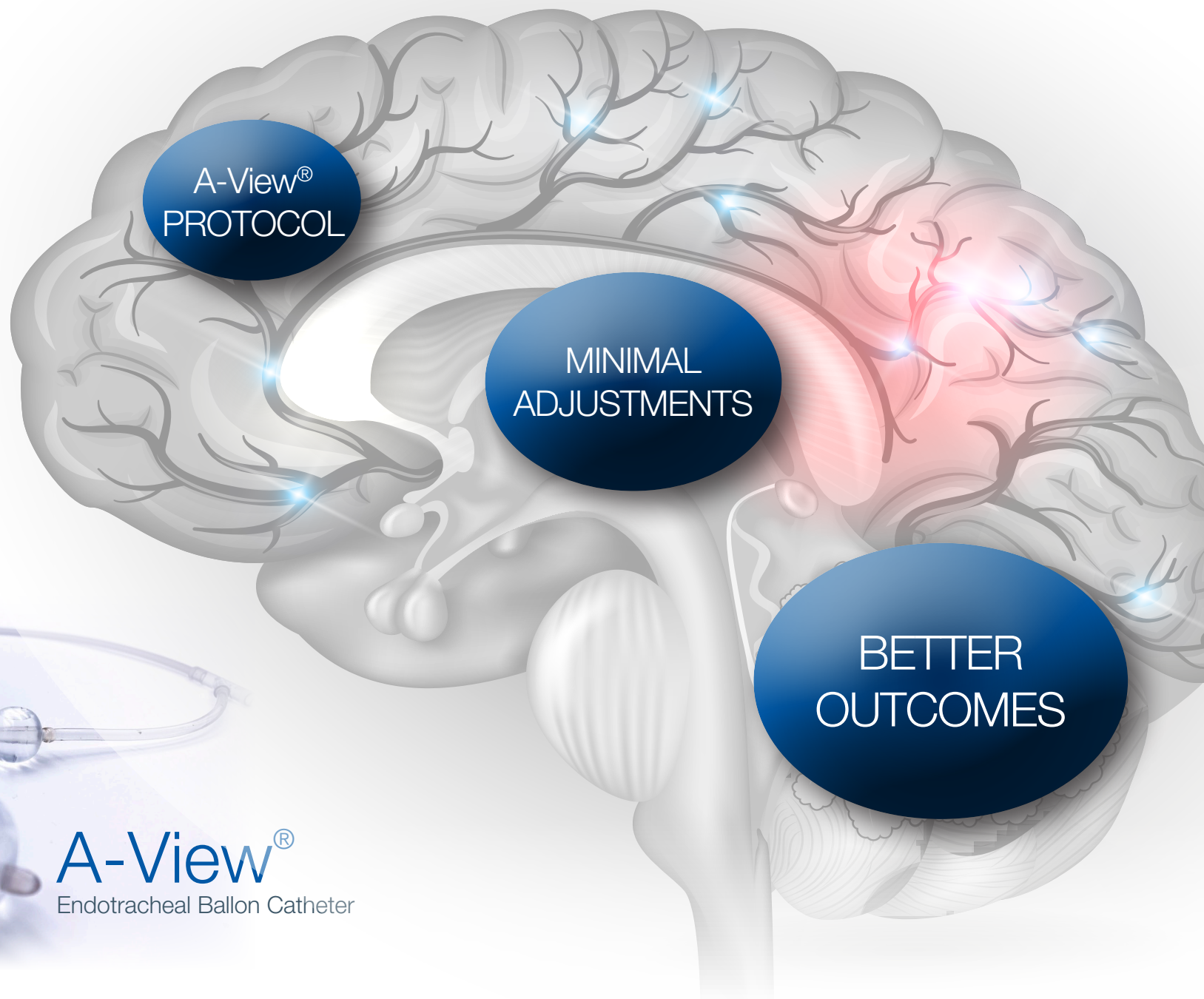
- 1. Is the A-View® balloon adequately filled?** Obtain an echo view of the trachea, the balloon should be aligned with the trachea wall, without any space in between. Adding additional saline should result in improved views.
- 2. Is the ET tube inserted too deep?** In case of a small patient e.g. short trachea, not enough room is left outside the ET tube for the balloon to be correctly positioned / inflated
- 3. Is the A-View® located in the right or left main bronchus?**
 - a) In short patients, view from the main bronchus is most effective
 - b) In tall patients, view through the carina or trachea is suggested
- 4. Is the aorta positioning altered?** For example a retracting sling around the aorta or a cross-clamp can impend TEE effectiveness.

Difficulties to obtain the aortic arch and branch vessels?

For a targeted anatomy, the A-View® balloon and TEE probe must be aligned to obtain effective views. If the TEE probe is sufficiently retracted cranially and still no accurate view can be obtained; the A-View® catheter might be placed too deep. This might be due to a short trachea (e.g. small stature of the patient) or the ET tube being positioned too deep.

To enable the missing views:

1. Empty the A-View® balloon
2. Empty the ET cuff
3. Withdraw the ET tube 2-3 cm
4. Retract the A-View® catheter 2-3 cm, align the 24 cm mark on A-View® and ET tube
5. Refill the A-View® sufficiently
6. Obtain the view: position TEE probe according to the guidelines



A-View[®]
Endotracheal Ballon Catheter



Improving Care. Improving Business.®

A-View is a registered trademark of Stroke2Prevent BV.
The DeRoyal logo and Improving Care. Improving Business. are registered trademark of DeRoyal Industries, Inc.
DeRoyal Industries, Inc. | 200 DeBusk Lane | Powell, TN 37849
1.800.DEROYAL or 865.938.7828 | www.deroyal.com
©2022, DeRoyal. All rights reserved. | Rev. 01/22 | Reprint #0-2545